

## Mucormycosis Associated with COVID-19

1<sup>st</sup> Janan K. AL-Tarjuman Ali <sup>1</sup> 2<sup>nd</sup> Fawwaz F. Ali <sup>2</sup> 3<sup>rd</sup> Safa M .Sultan <sup>3</sup>

Email: 1. [janankhorshed@ntu.edu.iq](mailto:janankhorshed@ntu.edu.iq)

2. [fawwaz@ntu.edu.iq](mailto:fawwaz@ntu.edu.iq)

3. [Safbio@ntu.edu.iq](mailto:Safbio@ntu.edu.iq)

1. Northern Technical University , Institute of Mosul , IRAQ.

2. Department of Scientifi Affairs, Northern Technical University, Mosul, Iraq.

Received: 23-2-2023, Accepted: 25-4-2023, Published online: 20-5-2023

**Abstract.** Coronavirus disease 2019 (COVID-19) outbreak firstly occurred in Wuhan, China, and quickly spread worldwide causing global public health threats. Bacterial and fungal infections are reportedly the common secondary infections correlated to viral pneumonia and lead to severe complications particularly in critically ill patients. This complication could lead to an increase in the demands for intensive care, and consequently increasing the rate of deaths. Despite the importance of these complications, few published articles reported a secondary infection, in particular those caused by fungi. Secondary infections were detected in 50% of COVID-19 patients who did not survive. Mucormycosis or called “black fungus” caused by the fungus mucormycete, significant fungal infection that fundamentally affects individuals who suffer from health problems or occupy medicines that lower the ability of the body to fight against germs and illnesses. So, in this review, we highlighted the currently available articles of secondary fungal infection related to COVID-19 infected patients. Thus, the current study rises the attention to the importance of fungal secondary infection, particularly from previously epidemics caused by the virus corona such as MERS and SARS) –COV diseases.

**Keywords:** COVID-19 , Mucormycosis , Secondary Infection.

### Introduction

Coronaviruses a member of the family *Coronaviridae* ( subfamily *Coronavirinae* , order *Nidovirales* ). This large family of viruses is characterized by high diversity, enveloped, single-stranded and positive-sense RNA. These viruses are responsible for a range of illnesses in humans and animals with variable severity ranged from mild disease including common cold to fatal severe acute respiratory syndrome (SARS) (1,2,3). In late 2012, a novel coronavirus was firstly diagnosed in the Middle East, which was called Middle East Respiratory Syndrome Coronavirus (MERS-CoV), resulted at least 50 laboratory-confirmed human infections (4,5,6). There is a belief that MERS-CoV virus is an animal origin virus that transmitted among humans (7). Between 2002 and 2003, SARS-COV firstly emerged in southern China and quickly spread around the world (8). In November 2002, Foshan, Guangdong, China pneumonia and high peak of nosocomial transmission took place among to health-care workers (9,10). On March 2003, a new corona virus was proven as the casual factor for sever acute respiratory syndrome SARS and was thus named SARS-COV (11,12,13,14). On the thirtieth of January 2020, a universal public health emergency was stated by the World Health Organization (WHO) (15) concerning the spread of

new Coronavirus called 2019-nCoV, the 2019 novel Coronavirus, emerged first in China, Hubei, Wuhan. On the eleventh of February, the disease formally was called as the coronavirus disease 2019 (COVID-19) by WHO and confirmed the transmission of disease from Human-to-human (16, 17) which occurred in US (18) Germany(19), and Vietnam(20). COVID-19 reached to 104 countries; 109,343 confirmed infections cases recorded on 9 March 2020 (21).

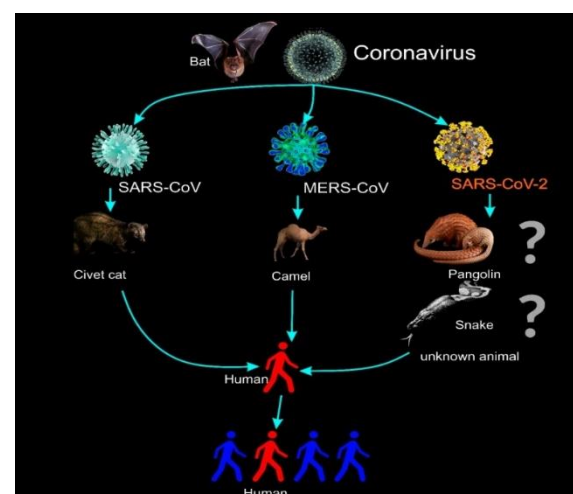


Figure 1. Animal origins of human coronaviruses.

In China, 50 million people had been locked down (22). To slow down the spread of COVID-19, Italy also undertook the same procedure (23). All coronaviruses which get illness to humans originated from animals bats or rodents. Bats, civet cats and dromedary camels are responsible for MERS-CoV and SARS-CoV transmission to humans. In COVID-19 case, pangolins was thought to be the responsible resource for the transmission (Figure1) (37).

### Signs and Symptoms

COVID-19 patients mostly had respiratory symptoms. In all the cases, fever was reported with cough and primarily dry shortness of breath. A considerable rate of patients seems to have gastrointestinal symptoms, including nausea, vomiting, and diarrhea (38).

### COVID-19 Co-Infection with Fungus:

Human fungal infection mainly differs from other diseases in various ways. Fungal pathogens are eukaryotic, so arrow many correspondences with their eukaryotic host cells. Fungi can infect large types of cells. A sole pathogenic fungus could infect various host tissues according to the immunological status of the patients (24,25). Fungi are not considered as significant pathogens by the public health official compared with diseases caused by bacteria, viruses, and protozoa, which have been known for centuries as urgent public health problems; for example, influenza, Chagas, and syphilis (24). However, only in 1980s, invasive mycoses medically realized as fundamental pathogens (26, 25). The infections of bacteria or fungi are represented in common complications of viral pneumonia, mostly in critically diseases patients, and result in the increased necessity for acute care and raised mortality. Bacterial co-infection in influenza patients was established in 0.5% and 2.5% of hale young and older people respectively (27, 28). Influenza virus causes ulceration of the trachea bronchial epithelium, thus, providing an opportunity for *Aspergillus* to cause invasive infection (29). A formal survey detects that H1N1 patients in 2009 had a bacterial or fungi infection at a rate of one in four patients (30). First reported with H1N1 influenza, invasive pulmonary aspergillosis(I-P-A) illustrates a frequent (20-30%) and early complication in critically ill influenza patients leading to enhanced illness severity and mortality rate (40-60%) (31,32). Influenza-associated aspergillosis (I-A) was

spotted in each flu season as well as influenza A and B pneumonia patients (34). The death rate at patients of severe influenza without I-A was 28% while in patients with I-A, it was 51% (32). Moreover, I-A co-infection appeared in patients who had underlying conditions (31,32). Gram-negative bacilli and candida were reported to be the general pathogens, in SARS patients. (33). Invasive pulmonary aspergillosis (I-P-A) was also stated as another common secondary complication to influenza infection (34). In a study that carried on a little brown bats (*Myotis lucifugus*) co-infection, it showed that the level of (CoV- RNA) in bats co-infected with white-nose syndrome (WNS) fungus is higher than bats infected with virus alone with the amount of (CoV- RNA) related with riskiness of WNS pathology in co-infected bats (7). A few information present on fungal and bacterial co-infection in patients infected with coronavirus pneumonia, 50% of COVID-19 patients mortality were having secondary infection (35). Noteworthy here that many factors are affecting the death rate in patients of COVID-19, viz: age, D-dimer, rate of organ failure and fungal and/or bacterial co-infection (35,28). Data collected from 27 intensive care unit (ICU ) patients for screening fungal secondary pneumonia infection in COVID-19; i.e. the infected patients who experienced bronchoalveolar lavage or bronchial aspirates, found that nine patients representing (33%) of COVID-19 patients were with putative invasive pulmonary aspergillosis (I-P-A). These patients were with I-P-A, including six patients confirming mycological condition and three patients founded with only *Aspergillus fumigates*. The current study represented a high prevalence of fungal co-infection compared with previous studies that investigated the fungal co-infection in influenza admitted patients(36). Theyse studies found that the putative I-P-A in one-third of successive critically ill COVID-19 patients were at a similar rate to what has been observed in influenza patients (31,32). Finally, fungal and bacterial co-infection in COVID-19 patients has not adequately been researched; we should exploit lessons from previously epidemic of (SARS-COV) and (MERS).

### Mucormycosis:

The atypical features of the new coronavirus illness (COVID-19) continue to have extraordinary global effects. The potential of opportunistic fungal infections, such as pulmonary aspergillosis and mucormycosis, which accompany viral

symptoms and may cause mortality by invading multiple organ systems is highlighted by new cases of SARS-CoV-2 infection (42).

While India was suffering from the spread of COVID-19, in second wave a new impendence was arising called the black fungus or mucormycosis. The moulds were responsible of the infection which are present in decaying vegetation and soil. As spores in the atmosphere, the infection mainly appear among patients recovered from Covid -19 but they have comorbidities like cancer, diabetes, heart or kidney failure. Individuals who have health problems or take medicines that decrease the resistance of the body against infection .The weak immunity Covid patients are more vulnerable to infected with this deadly infection (40,41)

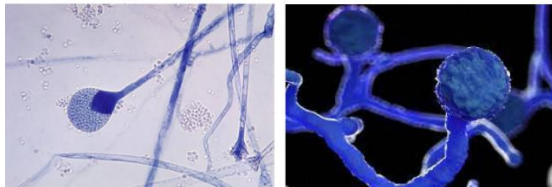


Figure 2. Mucormycetes ( 40 ).

### The Symptoms of Mucormycosis Related to COVID-19

In the recovered Covid-19 patient, the black fungus or mucormycosis started to signs after 2-3 days from clearing begin in the sinus and advance to the eyes. In the following 24 hours, the black fungus will propagation to the brain. Mucormycosis symptoms vary according to the development of infection in the body. Unilateral swelling of the face, sinus inflammation or nasal, cough, fever as well as the blackish lesions on nasal bridge blurry vision with double appearing objects, tissues thrombosis, dermal cells necrosis and haemoptysis or coughing blood. Fever, chest pressure, cough, and breath shortness are the symptoms of lung mucormycosis (40 ,41). Most mucormycosis patients (59 [74%] of 80 patients) had rhinoorbital cerebral infection, with extension into the CNS proven in 22 (37% of 59 individuals). Patients from India, where 41 (98%) of 42 patients developed rhino-orbital cerebral infection (with evidence of cerebral involvement in 11 [27%] of 41 patients), were especially prone to the condition. Twenty patients representing (25%) had pulmonary illness, three of whom had disseminated mucormycosis with involvement of the sinus (one patient) or CNS (two patients). Besides, one patient had gastrointestinal

mucormycosis of the 20 patients with pulmonary illness, 18 (90%) had severe or serious COVID-19, with the majority of these patients (15 [83%] of 18) being admitted to the intensive care unit. Only four of the 55 patients with rhino-orbital cerebral disease who had diabetes and rhino-orbital cerebral mucormycosis had blood sugar levels that were under control. In contrast, patients with other clinical manifestations of mucormycosis (20 with pulmonary and one with gastrointestinal COVID-19-associated mucormycosis) were less likely to have diabetes (11 [52%] of 21, the four of whom had well-controlled blood sugar concentrations (43).

### Risk Factors of Mucormycosis

People with uncontrolled diabetes mellitus, diabetic ketoacidosis, a history of corticosteroid therapy (44) organ or bone marrow transplants, other types of metabolic acidosis, neutropenia (45) elevated serum iron levels (46) deferoxamine or iron chelation therapy in hemodialysis patients (47) and malignant hematologic disorders (47) are at risk. In addition to raising blood glucose levels that were already high or uncontrolled in diabetics, steroid usage also caused blood sugar levels in prediabetic and diabetic individuals to rise 79% of the patients in the study who had diabetes and a fungus infection at the time of presentation (42). Increased steroid usage in COVID-19 patients may help to partly explain the rise in mucormycosis instances (48, 42).

Tropical and sub-tropical humid climate environmental factors additionally, much of India has high temperatures in the climate. appeared to be a factor in the frequency of the condition (49).

New risk factors were introduced by the COVID-19 pandemic to the growing mucormycosis epidemic. A new COVID-19 wave was presently affecting India, posing difficulties for the nation's healthcare system. India may have several contributing factors to its much greater frequency of COVID-19-induced mucormycosis, including poorly managed diabetes, excessive corticosteroid usage, potential antibiotic use and environmental exposure (50).

### Treatment of Mucormycosis Associated with COVID-19

A timely combination of surgery and antifungal medication was used to treat COVID-19-associated mucormycosis. Sinonasal debridement is the most

common kind of surgery. In their comprehensive study which examined COVID-19 mucormycosis patients who died and those who survived, researchers found a correlation between surgery and antifungal medication and greater survival rates (42). With the exception of three individuals, systemic antifungal medications were employed to treat mucormycosis. The majority of patients (71 [89%] of 80) received amphotericin B formulations, while six patients with rhino-orbital cerebral mucormycosis also received posaconazole. Five patients received isavuconazole either as monotherapy, as salvage treatment, or in combination with amphotericin B (two patients each) (one patient). In addition, 45 patients (58%) received surgical excision (43 (96%), of whom 16 who had orbital exenteration, had rhinoorbital cerebral mucormycosis) (43).

## Conclusion

Previous studies have shown that a fungus and a virus could interact during co-infection and affect each other; bacterial and fungal secondary infection could be a decisive agent in the death of COVID-19 patients who received inadequate attention.

## Acknowledgment

The authors are very grateful to Northern Technical University and Mosul Technical institute for providing the facilities which helped to improve the quality of the current study.

## References

- [1] Woo, P. C. ; Lau, S. K. ; Huang, Y. and Yuen, K. Y. (2009). Coronavirus diversity, phylogeny, and interspecies jumping. *Exp. Biol. Med.* (Maywood) 234, 1117–1127.
- [2] Chan, J.F.; Li KS; To, K.K.; Cheng, V.C.; Chen, H. and Yuen, K.Y.(2012). [Is the discovery of the novel human betacoronavirus 2c EMC/2012 \(HCoV-EMC\) the beginning of another SARS-like pandemic?](#). *J. Infect.* 65(6):477-89.
- [3] Chan, J.F.; Lau, S.K., and Woo, P.C. (2013). The emerging novel Middle East respiratory syndrome coronavirus: the 'knowns' and 'unknowns'. *J. Formos. Med. Assoc.* 112, 372–381.
- [4] WHO. Naming of the Novel Coronavirus. Available at [http://www.who.int/csr/disease/coronavirus\\_infections/NamingCoV\\_28May13.pdf](http://www.who.int/csr/disease/coronavirus_infections/NamingCoV_28May13.pdf).
- [5] Cheng, V.C.; Lau, S.K.; Woo, P.C., and Yuen, K.Y. (2007). Severe acute respiratory syndrome coronavirus as a novel agent of emerging and reemerging infection. *Clin. Microbiol. Rev.* 20, 660–694.
- [6] Chan, J.F.; Lau, S.K.; To, K.K.; Cheng, V.C.; Woo, P.C. and Yuen, K.Y. (2015). Middle East respiratory syndrome coronavirus: another zoonotic betacoronavirus causing SARS-like disease. *Clin. Microbiol. Rev.* 28(2):465-522.
- [7] Davy, C.M.; Donaldson, M.E.; Subudhi, S.; Rapin, N.; Warnecke, L.; Turner, J.M.; Bollinger, T.K.; Kyle, C.J.; Dorville, N.A.S.; Kunkel, E.L.; Norquay, K.J.O.; Dzal, Y.A.; Willis, C.K.R. and Willis, V. (2018). White-nose syndrome is associated with increased replication of a naturally persisting coronavirus in bats. *Science Reports*. 8(15508): 1-12.
- [8] Zumla, A., Chan, J.F.W., Azhar, E.I., Hui, D.S.C., and Yung, K.Y. (2016). Coronavirus - drug discovery and therapeutic options. *Nature Reviews Drug Discovery*. 10.1038/1-21.
- [9] [Zhao, Z.; Zhang, F.; Xu, M.; Huang, K.; Zhong, W.; Cai, W.; Yin, Z.; Huang, S.; Deng, Z.; Wei, M.; Xiong, J. and Hawkey, P.M. \(2003\). Description and clinical treatment of an early outbreak of severe acute respiratory syndrome \(SARS\) in Guangzhou, PR China. \*J. Med. Microbiol.\* 52\(8\):715-720.](#)
- [10] Xu, R.H.; He, J.F.; Evans, M.R.; Peng, G.W.; Field, H.E.; Yu, D.W.; Lee, Hui-Min Luo, C.K.; Lin, W.S.; Lin, P.; Li, L.H.; Liang, W.J.; Lin, J.Y. and Schnur, A. (2004). Epidemiologic Clues to SARS Origin in China. *Emerg Infect Dis.* 10(6): 1030–1037.
- [11] Peiris, J.S.; Lai, S.T.; Poon, L.L.; Guan, Y.; Yam, L.Y.; Lim, W.; Nicholls, J.; Yee, W.K.; Chan, W.W.; Cheung, M.T.; Cheng, V.C.; Chan, K.H.; Tsang, D.N.; Yung, R.W.; Ng, T.K. and Yuen, K.Y. (2003). Coronavirus as a possible cause of severe acute respiratory syndrome. *Lancet*. 361(9366):1319-25.
- [12] Kuiken, T.; Fouchier, R.A.; Schutten, M.; Rimmelzwaan, G.F.; van Amerongen, G.; van Riel, D.; Laman, J.D.; de Jong, T.; van Doornum, G.; Lim, W.; Ling, A.E.; Chan, P.K.; Tam, J.S.; Zambon, M.C.; Gopal, R.; Drosten, C.; van der Werf, S.; Escriou, N.; Manuguerra, J.C.; Stöhr, K.; Peiris, J.S. and Osterhaus, A.D. (2003). Newly discovered coronavirus as the primary cause of severe acute respiratory syndrome. *Lancet*. 26: (9380):263-70.
- [13] Drosten, C.; Günther, S.; Preiser, W.; van der Werf, S.; Brodt, H.R.; Becker, S.; Rabenau, H.; Panning, M.; Kolesnikova, L.; Fouchier, R.A.; Berger, A.; Burguière, A.M.; Cinat, I.; Eickmann, M.; Escriou, N.; Grywna, K.; Kramme, S.; Manuguerra, J.C.; Müller, S.; Rickerts, V.; Stürmer, M.; Vieth, S.; Klenk, H.D.; Osterhaus, A.D.; Schmitz, H. and Doerr, H.W. (2003). Identification of a novel coronavirus in patients with severe acute respiratory syndrome. *N Engl J Med.* 348(20):1967-76.

- [14] [Ksiazek, T.G.](#); [Erdman, D.](#); [Goldsmith, C.S.](#); [Zaki, S.R.](#); [Peret, T.](#); [Emery, S.](#); [Tong, S.](#); [Urbani, C.](#); [Comer, J.A.](#); [Lim, W.](#); [Rollin, P.E.](#); [Dowell, S.F.](#); [Ling, A.E.](#); [Humphrey, C.D.](#); [Shieh, W.J.](#); [Guarner, J.](#); [Paddock, C.D.](#); [Rota, P.](#); [Fields, B.](#); [DeRisi, J.](#); [Yang, J.Y.](#); [Cox, N.](#); [Hughes, J.M.](#); [LeDuc, J.W.](#); [Bellini, W.J.](#) and [Anderson, L.J.](#) (2003). A novel coronavirus associated with severe acute respiratory syndrome. *N Engl J Med.* 348(20):1953-66.
- [15] Novel Coronavirus (2019-nCoV), Situation Report 11. Available online: [https://www.who.int/docs/default-source/coronaviruse/situation-reports/20200131-sitrep-11-ncov.pdf?sfvrsn=de7c0f7\\_4](https://www.who.int/docs/default-source/coronaviruse/situation-reports/20200131-sitrep-11-ncov.pdf?sfvrsn=de7c0f7_4) (accessed on 13 March 2020).
- [16] Novel Coronavirus (2019nCoV) Situation Report 48. Available online: [https://www.who.int/docs/default-source/coronaviruse/situationreports/20200308-sitrep-48-covid-19.pdf?sfvrsn=16f7ccef\\_4](https://www.who.int/docs/default-source/coronaviruse/situationreports/20200308-sitrep-48-covid-19.pdf?sfvrsn=16f7ccef_4) (accessed on 13 March 2020).
- [17] How 2019-nCoV spreads. Available online: <https://www.cdc.gov/coronavirus/2019-ncov/about/transmission.html> (accessed on 13 March 2020).
- [18] [Holshue, M.L.](#); [DeBolt, C.](#); [Lindquist, S.](#); [Lofy, K.H.](#); [Wiesman, J.](#); [Bruce, H.](#); [Spitters, C.](#); [Ericson, K.](#); [Wilkerson, S.](#); [Tural, A.](#); [Diaz, G.](#) and [Cohn, A.](#) (2020). First Case of 2019 Novel Coronavirus in the United States. *N. Engl. J. Med.* 382, 929–936.
- [19] [Rothe, C.](#); [Schunk, M.](#); [Sothmann, P.](#); [Bretzel, G.](#); [Froeschl, G.](#); [Wallrauch, C.](#); [Zimmer, T.](#); [Thiel, V.](#) and [Janke, C.](#) (2020). Transmission of 2019-nCoV Infection from an Asymptomatic Contact in Germany. *N. Engl. J. Med.* 382, 970–971.
- [20] [Phan, L.T.](#); [Nguyen, T.V.](#); [Luong, Q.C.](#); [Nguyen, T.V.](#); [Nguyen, H.T.](#); [Le, H.Q.](#); [Nguyen, T.T.](#); [Cao, T.M.](#); [Pham, Q.D.](#) (2020). Importation and Human-to-Human Transmission of a Novel Coronavirus in Vietnam. *N. Engl. J. Med.* 382, 872–874.
- [21] WHO, Novel Coronavirus, Situation Dashboard. Available online: <https://www.who.int/emergencies/diseases/novel-coronavirus-2019/situation-reports/> (accessed on 9 March 2020).
- [22] [Cohen, J.](#) and [Kupferschmidt, K.](#) (2020). Strategies shift as coronavirus pandemic looms. *Science.* 367, 962–963.
- [23] Italy Announces Lockdown as Global Coronavirus Case Surpass 105,000. Available online: <https://edition.cnn.com/2020/03/08/asia/coronavirus-covid-19-update-intl-hnk/index.html> (accessed on 8 March 2020).
- [24] [Brachman, P.S.](#) (2003). Infectious diseases—Past, present, and future. *International Journal of Epidemiology.* 32 : 684 – 686.
- [25] [Rodrigues, M.L.](#) and [Nosanchuk, J.D.](#) (2020). Fungal diseases as neglected pathogens: A wake-up call to public health officials. *PLOS Neglected Tropical Diseases.* 14(2):1-9.
- [26] [Nucci, M.](#) and [Marr, K.A.](#) (2005). Emerging fungal diseases. *Clin Infect Dis.* 41(4):521-6.
- [27] [Chertow, D.S.](#) and [Memoli, M.J.](#) (2013). Bacterial coinfection in influenza: a grand rounds review. *JAMA.* 309:275-282.
- [28] [Zhou, P.](#); [Liu, Z.](#); [Chen, Y.](#); [Xiao, Y.](#); [Huang, X.](#) and [Fan, X.](#) (2020) Bacterial and fungal infections in COVID-19 patients: A matter of concern. *Infection Control & Hospital Epidemiology.* 10(1017):1-7.
- [29] [Gill, J.R.](#); [Sheng, Z.M.](#); [Ely, S.F.](#); [Guinee, D.G.](#); [Beasley, M.B.](#); [Suh, J.](#); [Deshpande, C.](#); [Mollura, D.J.](#); [Morens, D.M.](#); [Bray, M.](#); [Travis, W.D.](#) and [Taubenberger, J.K.](#) (2010). Pulmonary pathologic findings of fatal 2009 pandemic influenza A/H1N1 viral infections. *Arch Pathol Lab Med.* 134:235–43.
- [30] [MacIntyre, C.R.](#); [Chughtai, A.A.](#); [Barnes, M.](#); [Riddal, S.](#); [Seale, H.](#); [Toms, R.](#) and [Heywood, A.](#) (2018). The role of pneumonia and secondary bacterial infection in fatal and serious outcomes of pandemic influenza A(H1N1)pdm09. *BMC Infect Dis* 2018;18:637.
- [31] [Wauters, J.](#); [Baar, I.](#); [Meersseman, P.](#); [Meersseman, W.](#); [Dams, K.](#); [De Paep, R.](#); [Lagrou, K.](#); [Wilmer, A.](#); [Jorens, P.](#) and [Hermans, G.](#) (2012). Invasive pulmonary aspergillosis is a frequent complication of critically ill H1N1 patients: a retrospective study. *Intens Care Med.* 38: 1761–8.
- [32] [Schauwvlieghe, A.F.A.D.](#); [Rijnders, B.J.A.](#); [Philips, N.](#) et al. (2018). Invasive aspergillosis in patients admitted to the intensive care unit with severe influenza: a retrospective cohort study. *Lancet Respir Medicine.* 6:782–92.
- [33] [Zheng, Z.](#); [Chen, R.](#); [Li, Y.](#) et al. The clinical characteristics of secondary infection of Lower respiratory in severe acute respiratory syndrome. (2003). *Chinese Journal of Respiratory and Critical Care Medicine.* 2(5):270-274.
- [34] [Rijnders, B.](#); [Schauwvlieghe, A.](#) and [Wauters, J.](#) (2020). Influenza-Associated Pulmonary Aspergillosis: A Local or Global Lethal Combination?. *Clinical Infectious Diseases*, 71: 7(1) : 1764–1767, <https://doi.org/10.1093/cid/ciaa010>
- [35] [Zhou, F.](#); [Yu, T.](#); [Du, R.](#); [Fan, G.](#); [Liu, Y.](#) et al. (2020). Clinical course and risk factors for mortality of adult inpatients with COVID-19 in Wuhan, China: a retrospective cohort study. *Lancet.* 395: 1054–62.
- [36] [Alanio, A.](#); [Delliè, S.](#); [Fodil, S.](#); [Bretagne, S.](#) and [Mégarbane, B.](#) (2020). High prevalence of putative invasive pulmonary aspergillosis in critically ill COVID-19 patients. *SSRN Electronic Journal DOI:10.2139/ssrn.3575581*
- [37] [Rabi, F.A.](#); [AlZoubi, M.S.](#); [Kasasbeh, G.A.](#); [Salameh, D.M.](#) and [Al-Nasser, A.D.](#) (2020). SARS-CoV-2 and Coronavirus Disease 2019: What We Know So Far. *Pathogens.* 9(231): 1-14.
- [38] [Lupia, T.](#); [Scabini, S.](#); [Pinna, S.M.](#); [Di Perri, G.](#); [De Rosa, F.G.](#) and [Corcione, S.](#) (2020). 2019-novel coronavirus outbreak: A new challenge. *Journal of Global Antimicrobial Resistance.* 21: 22-27.
- [39] [Nguyen, T.](#); [Bang, D.D.](#) and [Wolff, A.](#) (2020). 2019 Novel Coronavirus Disease (COVID-19): Paving the Road for Rapid Detection and Point-of-Care Diagnostics. *Micromachines.* 11(306):3-7.
- [40] [Kameshwaran, Dr.S.](#); [Sriram, Dr.N.](#); [Darla, R.](#)



- Manimekalai, Dr.P.; Dhanalakshmi , M. (2021). Symptoms and treatment strategy of black fungus in Covid-19 patients . *Int. J. of Pharmacology and Clin. Research* Vol-5(2) 2021 [24-27] .
- [41] Bhat, I.; Beg, Md. A.; Athar, F. (2021). A contemporary intimidation for COVID-19 patients coinfectd with mucormycosis in India. *Journal of Bacteriology & Mycology: Open Access*.9(2).69-71.
- [42] Dilek , A.; Ozaras,R.; Ozkaya,S.; Sunbul,M.; Itir Sen,E.; Leblebicioglu,H.(2021). COVID-19-associated mucormycosis: Case report and systematic review. *Travel Medicine and Infectious Disease* 44 . 102148 : 1-9 .
- [43] Hoenigl,M.; Seidel,D.; Carvalho,A.; Rudramurthy,S.M.; Arastehfar,A.; Gangneux,J.; Nasir,N.; Bonifaz,A.; Araiza,J.; Klimko,N.; Serris,A.; Lagrou,K.; Meis,J.F.; Cornely,O.A.; Perfect,J.R.; White,P.L. and Chakrabarti,a.( 2022). The emergence of COVID-19 associated mucormycosis: a review of cases from 18 countries . *Lancet Microbe* .3: e543–52.
- [44] Waizel-Haiat S, Guerrero-Paz JA, Sanchez-Hurtado L, Calleja- Alarcon S, Romero-Gutierrez L (2021) A case of fatal rhinoorbital mucormycosis associated with new onset diabetic ketoacidosis and COVID-19. *Cureus* 13(2):e13163 .
- [45] Serris A, Danion F, Lanternier F (2019) Disease entities in mucormycosis. *J Fungi* 5(1):23
- [46] Ibrahim AS, Spellberg B, Walsh TJ, Kontoyiannis DP (2012) Pathogenesis of mucormycosis. *Clin Infect Dis* 54:1–7
- [47] Hirabayashi KE, Idowu OO, Kalin-Hajdu E et al (2019) Invasive fungal sinusitis: risk factors for visual acuity outcomes and mortality. *Ophthalmic Plast Reconstr Surg* 35:535–542 .
- [48] Sugar,A.M. Mucormycosis. *Clin Infect Dis* 1992;14(Suppl 1):S126–9.
- [49] Chakrabarti A and Singh R.(2011) The emerging epidemiology of mould infections in developing countries. *Curr Opin Infect Dis* 24:521–6.
- [50] Singh, A.A.; Singh, R.; Joshi, S.R. and Misrac, A. (2021) . Mucormycosis in COVID-19: a systematic review of cases reported worldwide and in India. *Diabetes Metab Syndr* .15 (4):102146. <https://doi.org/10.1016/j.dsx.2021.05.019>.